

A transplantable insulinoma in the rat

(insulin/blood glucose hypoglycemia/pancreatic islets/somatostatin)

WILLIAM L. CHICK*†, SHIELDS WARREN‡, ROSANNA N. CHUTE‡, ARTHUR A. LIKE§, VILMA LAURIS*, AND KYLE C. KITCHEN*

* Elliott P. Joslin Research Laboratory, Harvard Medical School, and the Peter Bent Brigham Hospital, Boston, Massachusetts 02215; † Cancer Research Institute, New England Deaconess Hospital, Boston, Massachusetts 02215; and § University of Massachusetts Medical School, Worcester, Mass. 01605

Contributed by Shields Warren, November 18, 1976

ABSTRACT A transplantable insulinoma was developed in inbred albino rats of the NEDH strain. The original tumor, 1 cm in diameter, was removed from the pancreas of a male parabiont 566 days following 1000 rads (10 J/kg) of total body x-irradiation. The time required for implanted fragments to grow to 0.5-1.5 cm in diameter decreased from 5-8 months in the first generation to 2-5 months in the seventh generation. Successful transplantation in male animals followed for 4 or more months after transplantation was significantly greater than in female animals followed for a similar period of time (96% versus 69%). Light and electron microscopy revealed that the tumors consisted predominantly of well-granulated beta cells. Ultrastructural studies also showed small numbers of D-cells. Tumor extracts contained an average of 223 units of immunoreactive insulin and 25.9 µg of immunoreactive somatostatin per gram wet weight of tissue. Tumors generally produced increasingly profound hypoglycemia within 2-4 months following transplantation, with plasma glucose levels frequently falling to 40 mg/100 ml or lower prior to death. Removal of tumors from chronically hypoglycemic animals resulted in transient rebound hyperglycemia with plasma glucose levels above 300 mg/100 ml within the first 24 hr and a gradual decline to normal levels of 129 mg/100 ml in 2-4 days. These observations correlated with findings of marked atrophy and degranulation of the beta cells in the pancreata of tumor-bearing animals, and with gradual return of normal light microscopic morphology following tumor removal.

Limitation of starting material has proven to be a serious obstacle in several important areas of pancreatic beta cell research. Although methods are available for isolating pancreatic islets by collagenase digestion and Ficoll gradient centrifugation, such procedures at best yield only a few milligrams of material (1, 2). This has made the preparation of subcellular fractions and the isolation of other constituents of the beta cell extremely difficult. Although a transplantable insulinoma developed several years ago in the hamster has provided relatively large amounts of tissue, the predominant cell types in this tumor remain unclear because the insulin content is extremely low and light microscopic sections fail to stain with appropriate aldehyde-type stains (3, 4).

The present studies involve experiments with a recently developed radiation-induced transplantable rat insulinoma that has made available gram quantities of well-granulated beta cells with high insulin content (5). This material has already proven valuable for the isolation of messenger RNA for insulin synthesis (6, 7) and for the initiation of studies towards the development of a permanent line of insulin-producing cells (8, 9). The present report describes the method used to develop and to transplant this tumor, and its morphology, hormone content, and physiological effects on host animals. The actions exerted by this in-

sulinoma on the recipient's own pancreatic islet cells are also described.

MATERIAL AND METHODS

Induction of Original Tumor and Subsequent Transplantation. The original tumor was observed in the irradiated partner of a pair of male parabiont NEDH albino rats 566 days after one partner received 1000 rads (10 J/kg) of total body x-irradiation (10-12). The two animals had been surgically separated 61 days after irradiation. The irradiated rat was moribund at 666 days of age, at which time the primary tumor, which was 1 cm in diameter, was removed from the pancreas. There was no gross evidence of either local or distant metastases. Small fragments of the original tumor, approximately 1 × 1 × 3 mm in size, were implanted subcutaneously in the interscapular region of six 6-week-old male NEDH rats using a no. 16 trocar. Four of these animals eventually developed positive transplants. Two of these transplants attained the size of 1.5 cm in 5 and 8 months and were removed and used to establish the tumor lines subsequently transplanted to all other recipients. These two first-generation tumors were then transplanted into 16 new recipients with a success rate of 100%.

To date, tumor lines have been propagated mainly by subcutaneous transplantation as already described. In addition, both intraperitoneal and intrahepatic transplants have also been successful. With the exception of the initial transplants, most tumors attained the size of 0.5-1 cm within approximately 4 months and were then removed for implantation into an average of four to six new hosts. The present study includes results involving approximately 236 animals (201 male and 35 females) that received transplants. All animals were fed ad lib. with Purina chow during the course of these experiments.

Morphology. For light microscopy, tumor fragments and the pancreata of host animals were fixed in Bouin's solution and embedded in paraffin, and sections were stained with hematoxylin and eosin and aldehyde fuchsin (13).

For electron microscopy, representative fragments of tumor were minced in 3% glutaraldehyde buffered with 0.1 M sodium cacodylate, postfixed in 1.33% osmium tetroxide in *sym*-collidine, and, after dehydration, embedded in a mixture of Epon and Araldite (14). The pancreata of host animals were fixed for electron microscopy by total body perfusion with a solution of paraformaldehyde (1%), glutaraldehyde (1.25%), and trinitroresol (0.02%), in 0.1 M phosphate buffer (pH 7.4) saturated with calcium chloride. After perfusion intervals of 5-10 min, the pancreata were cut into fragments in fresh fixative, and after an additional period of fixation, islets were dissected with the assistance of a Wild binocular dissecting microscope. The islets were postfixed in phosphate-buffered osmium tetroxide, dehydrated, and embedded in Epon-Araldite. One micrometer sections of tumor fragments or islets were prepared for light

Abbreviation: IRI, immunoreactive insulin.

† To whom correspondence should be addressed: Elliott P. Joslin Research Laboratory, 170 Pilgrim Road, Boston, Mass. 02215.

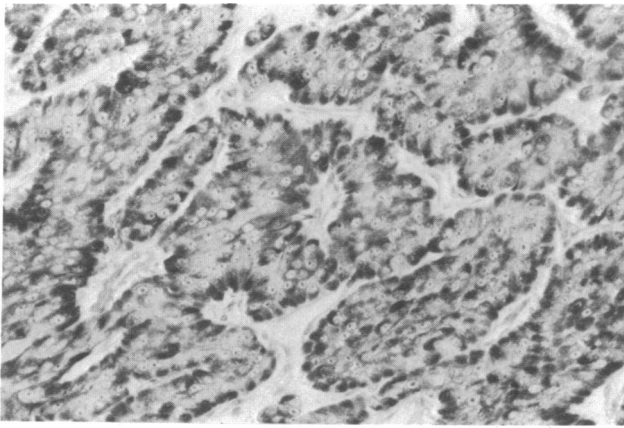


FIG. 1. Light micrograph of transplanted beta cell tumor (insulinoma) removed from its subcutaneous site after fifth passage. Aldehyde-fuchsin-positive secretory granules (black in photograph) are abundant. Aldehyde-fuchsin, $\times 256$.

microscopic study and the identification of areas of interest. Subsequently, thin sections were cut with DuPont diamond knives, mounted on copper grids, and examined in a Phillips 301 electron microscope after sequential staining in uranyl acetate and lead citrate.

Body Weight, Plasma Glucose, and Serum Insulin Determinations. Blood samples were obtained in the mornings by tail bleeding. Body weight and nonfasting plasma glucose levels were determined at 1-month intervals both in animals receiving tumor implants and in control rats from the same strain. Plasma glucose levels were measured using a Beckman glucose analyzer. In order to investigate possible effects of these tumors in suppressing normal pancreatic beta cell function, circulating glucose levels were also measured at daily intervals for several days following the surgical removal of subcutaneous insulinomas from a number of animals.

Serum immunoreactive insulin (IRI) was measured in representative tumor-bearing and control animals using the double antibody immunoassay technique (15, 16) with purified rat insulin standards (kindly provided by J. Schlichtkrull, Novo Research Laboratories). Simultaneous plasma glucose analyses were also performed in order to permit calculations of glucose:insulin ratios (17, 18).

Hormone Content of Tumors. Representative tumors were removed and immediately frozen either on aluminum foil or in plastic Falcon dishes placed directly on a block of dry ice. Portions of tumor were weighed and extracted with acid ethanol, and aliquots of these extracts were diluted with albumin-borate buffer and analyzed for immunoreactive insulin content as already described (15, 16). Results were expressed as insulin immunoreactivity, although preliminary data suggest these figures include significant quantities of immunoreactive precursors such as proinsulin (D. F. Steiner and S. Chan, personal communication), as is the case with human insulinomas (19). Levels of immunoreactive somatostatin were also determined by extracting portions of tumor by homogenization in 2 M acetic acid and subsequently analyzing by radioimmunoassay, using a modification (20) of the unpublished method of Patel and Reichlin.

RESULTS

Gross and Microscopic Appearance of Tumors. The original tumor was a 1 cm diameter, encapsulated mass located in the duodenal portion of the pancreas. Microscopic examination revealed some invasion of the surrounding capsule, blood ves-

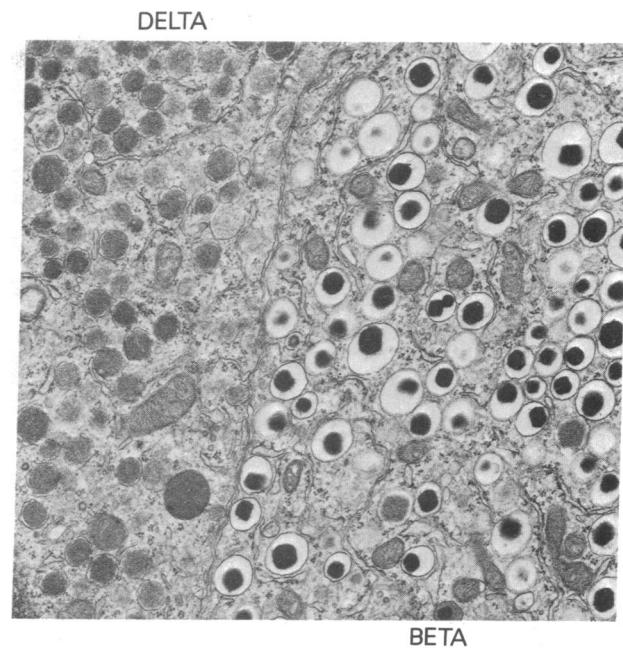


FIG. 2. Electron micrograph illustrating both beta and delta cell components of the transplanted tumor. The ultrastructural appearance of the beta cells cannot be distinguished from normal. Beta secretory granules are plentiful, and both dense and pale types are present. The numerous delta secretory granules fill the granule-limiting membranes and are of lower electron density than the dense beta granules. Approximately $\times 15,000$.

sels, and lymphatics. Occasional mitotic figures were also noted.

Subsequent subcutaneous transplants of this tumor generally reached a size of 0.5–1 cm in diameter within approximately 4 months. The tumor nodule or nodules were enmeshed in a dense fibro-collagenous matrix containing small blood vessels, enclosed adipocytes, and a variable quantity of hemosiderin pigment. The tumor cells were epithelial in appearance, oval to columnar in shape, frequently organized in cords, columns or clusters, and in close proximity with small, dilated, thin-walled vessels. Aldehyde-fuchsin-positive cytoplasmic granules were plentiful, and in favorably oriented sections appeared to be concentrated at the vascular pole of the cells (Fig. 1). Evidence of mitotic division among insulinoma cells was variable.

The ultrastructural appearance of the tumor cells could be differentiated from that of normal resting rat beta cells only by the presence of increased quantities of rough endoplasmic reticulum, by the variable cell size, and by the absence of the usually numerous adjacent capillaries. The secretory granules could not be distinguished from those of nonneoplastic beta cells with assurance; dense and pale granules were abundant and other organelles were normal in appearance (Fig. 2). Although architectural and cellular preservation was not optimal after immersion fixation, tumor cells containing classical delta secretory granules were identified occasionally, but with confidence (Fig. 2). Alpha cells have not been identified in the tumors examined to date.

Morphology of Host Animal's Pancreatic Islets. The endogenous islets of Langerhans in host animals sacrificed with a tumor *in situ* were strikingly reduced in size, somewhat less regular in contour, and populated by decreased numbers of beta cells containing only small numbers of aldehyde-fuchsin-positive granules (Fig. 3). The peripherally situated alpha cells were relatively increased in number, but of normal size and staining

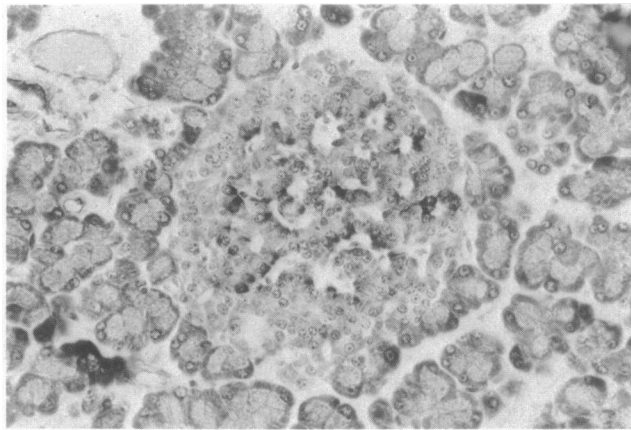


FIG. 3. Light micrograph of suppressed pancreatic islets of rats with transplantable insulinoma and hypoglycemia. Suppression of beta cell function is evidenced by smaller size of beta cells and decreased aldehyde-fuchsin-positive granule content. The peripheral pink staining alpha cells are relatively increased in number. In rats, beta cells are centrally located within the islet and surrounded by a mantle of alpha and delta cells. Aldehyde-fuchsin, $\times 256$.

quality. The magnitude of the reduction in islet size was variable and best appreciated by comparing the islets of tumor-bearing animals with normal islets after identical fixation and staining. In an occasional rat, beta cells could be identified within suppressed islets only with considerable difficulty.

Rates of Successful Transplantation. Animals were considered to have a successful transplant based either on palpation, direct visualization of the tumor at the time of removal, or a finding of a plasma glucose level of 100 mg/100 ml or less, which is more than three standard deviations lower than the mean of 129 mg/100 ml for control animals. Only animals that had been followed for a minimum of 4 months postimplantation were included in determining the rates of success in transplantation because some sublines of the tumor were slow-growing and required this period of time either to become palpable or to exert significant blood-sugar-lowering effects. Based on these criteria, of 236 animals studied, an overall success rate of 92% was achieved within this 4-month period (Table 1). Interestingly, the success rate in males (96%) was significantly greater than that in females (69%). The reasons for this difference are presently unclear, but may relate to the fact that the original tumor from which all subsequent lines were derived arose in a male animal.

Body Weights, Blood Glucose, and Serum Insulin Levels. These tumors produced a number of significant changes in host animals. Within 2–4 months following subcutaneous implantation of a small tumor fragment, a significant and progressive decline in blood sugar levels was generally noted. Interestingly, this decline in plasma glucose levels occasionally occurred prior to the tumor's achieving a palpable size. Typical alterations in plasma glucose levels in two groups of representative animals

Table 1. Rates of successful tumor transplantation in male and female recipients

	Male	Female	Total
Number of recipients	201	35	236
Number positive (%)	192 (96%)	24 (69%)	216 (92%)
Number negative* (%)	9 (4%)	11 (31%)	20 (8%)

* Animals were followed a minimum of 4 months after transplantation before being considered negative (see text).

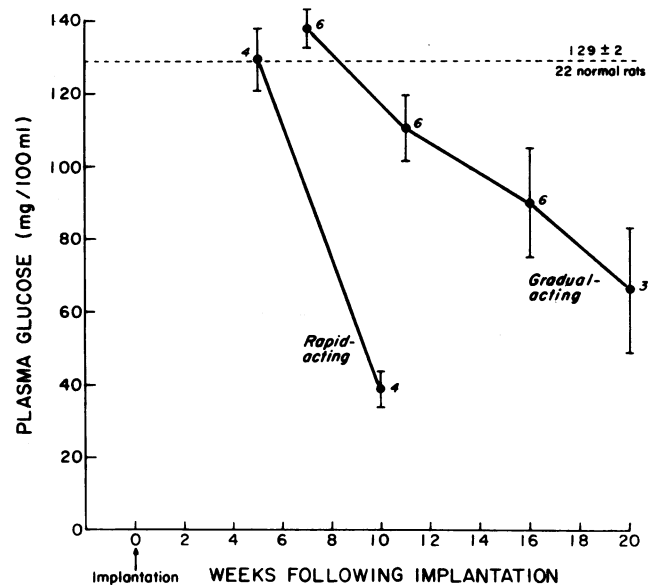


FIG. 4. Plasma glucose levels in host animals following subcutaneous transplantation of tumor fragments. Data are for two separate groups of male animals from the fifth transplant generation, approximately 7 weeks old at the time of transplantation. One group of four animals received implants from a tumor with rapid plasma-glucose-lowering effects, while the other group of six animals received implants from a slower-acting tumor. The broken line indicates the plasma glucose level for 22 normal male rats. Values are mean \pm SEM. The adjacent numerals indicate the number of animals used to compute each point.

are shown in Fig. 4. As can be seen, the mean plasma glucose levels frequently fell below 50 mg/100 ml prior to tumor removal. It is perhaps noteworthy that, for reasons which are presently unclear, the rate of fall in plasma glucose levels produced by different sublines of the tumor varied. Although both groups of male animals shown in Fig. 4 were from the fifth transplant generation and of similar age, they received implants from two different tumors. The difference in the rate of decline in plasma glucose produced by these two tumor sublines is readily apparent.

Animals generally became moribund 4–5 months after transplantation of the tumor, at which time a rasping respiration and partial limb paralysis were frequently noted. Body weights also tended to decline during this final phase prior to death.

Serum immunoreactive insulin determinations in representative animals revealed an average insulin level above that of normal controls. Perhaps more impressive was the statistically significant decrease in plasma glucose to insulin ratios observed in tumor-bearing animals (Table 2); this was the result of disproportionately high circulating IRI levels despite depressed plasma glucose concentrations.

In a number of animals the subcutaneous tumors were surgically resected, the wound was sutured, and the animal was allowed to recover. Plasma glucose levels were then determined at daily intervals. As anticipated from the morphology of the host animal's islets, tumor removal from these chronically hypoglycemic animals was followed by a marked rebound hyperglycemia with plasma glucose levels rising to 300–400 mg/100 ml plasma. This sharp increase in glucose levels was followed by a gradual return towards normal (Fig. 5).

Hormone Content of Tumors. Analysis of acid ethanol extracts of representative tumors revealed an insulin content ranging from 61 units/g of wet weight in the original tumor to as high as 452 units/g of wet weight in subsequent transplants.

Table 2. Plasma glucose/serum insulin relationships in tumor-bearing animals

Group	Number of animals	Serum IRI (μ U/ml)	Plasma glucose (mg/100 ml)	Glucose/IRI
Control	4	86 \pm 7	142 \pm 17	1.67 \pm 0.18
Tumor	9	163 \pm 36	63 \pm 8*	0.50 \pm 0.11*

Values are mean \pm SEM

* The differences compared to the corresponding control group are statistically significant to at least the $P < 0.05$ level (Student's t test).

The average insulin content for five tumors was 223 \pm 66 units (mean \pm SEM) per g of wet weight. In addition to these findings of high insulin content, results of preliminary analyses revealed significant levels of immunoreactive somatostatin in representative tumors. The immunoreactive somatostatin content of four different tumors ranged from 19.1 to 37.2 μ g/g of wet weight, with an average of 25.9 \pm 4.2 μ g/g (mean \pm SEM).

DISCUSSION

The tumor described in the present study possesses a number of interesting features. Although histologically neoplastic, the ultrastructural appearance of the insulinoma cells differs from that of nonneoplastic beta cells only as a result of the following: the rough endoplasmic reticulum is more plentiful in tumor cells; secretory granules, although classically of the beta cell type, are somewhat more varied in size and electron density and are more frequently smaller than in nontumor beta cells. Pale staining granules, although frequent, are not observed more often than in nonneoplastic beta cells.

The above listed features, therefore, emphasize the fact that the tumor cells were morphologically well-differentiated, and therefore, correlate well with the evidence of functional activity. These cells are capable of synthesizing and storing substantial quantities of insulin as evidenced by IRI levels in these tumors in addition to marked granulation evident on morphologic study.

The observed alterations within the host animal's islets of

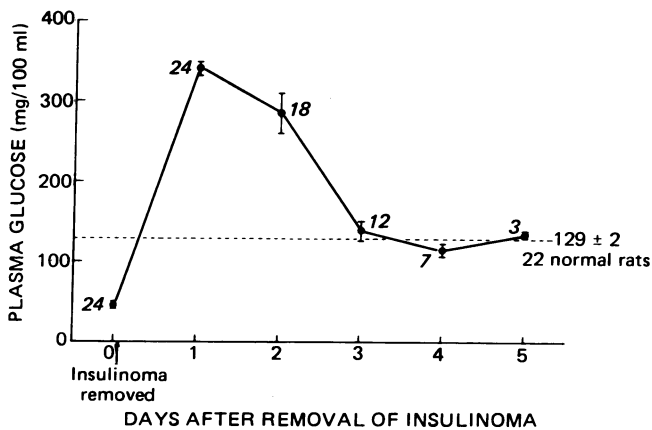


FIG. 5. Plasma glucose levels following surgical removal of tumors from host animals. Following tumor removal, groups of animals were sacrificed at daily intervals in order to correlate these changes in plasma glucose levels with alterations in pancreatic islet cell morphology (see *text*). The broken line indicates the mean plasma glucose level for 22 normal male rats. Values are mean \pm SEM. The adjacent numerals indicate the number of animals used to compute each point.

Langerhans provide further evidence of functional activity on the part of the insulinoma cells. The decreased number and size of the islet beta cells and the decreased number of cytoplasmic aldehyde-fuchsin-staining granules are features previously described in islets of rats treated for prolonged periods of time with large quantities of exogenous insulin (21, 22). The period of hyperglycemia that followed resection of the tumors is also consistent with long-standing beta cell suppression and is also observed after prolonged periods of insulin administration in rats (23, 24). Although it is conceivable that release of somatostatin from the small number of D-cells within these tumors may also have contributed to this suppression (25), there is presently no direct evidence from our studies to support this hypothesis.

It is readily apparent that these morphologically differentiated transplantable insulinomas are of potential value in several areas of beta cell research where limitation of starting material has posed serious difficulties, as already noted. Two areas where they have already proven extremely useful include studies involving early steps in insulin synthesis (6) and the isolation and purification of messenger RNA for preproinsulin synthesis (7). Additional areas of application might include isolation and analysis of beta cell plasma membranes, particularly with a view towards further elucidating the mechanisms that regulate insulin secretion. These tumors may also furnish a means for establishing a permanent line of insulin-producing cells in tissue culture, as has been the case with several other types of cultured endocrine cell lines derived from rodent tumors (26, 27).

Finally, it is of note that of several x-ray-induced tumors of rat islet cells transplanted during the past years, the only success achieved to date has been the one tumor described in this report (S. Warren and R. N. Chute, unpublished observations). It is of further interest that recent experiments suggest that a small percentage of drug-induced insulinomas produced by the injection of streptozotocin and nicotinamide (28-30) into Wistar-Lewis rats are also transplantable (W. L. Chick, V. Lauris, and R. N. Chute, unpublished observations).

It is of interest to speculate whether new transplantable islet cell tumors produced either by radiation or by drugs will differ significantly from the present tumor with regard to morphology, biochemistry, and physiologic behavior. If so, a series of such tumors may furnish further insight into the mechanisms that regulate islet cell function.

We are indebted to Dr. Gordon Weir for determining the somatostatin content of representative tumors. We also thank Ms. Brigita Krastins for her skillful technical assistance and Ms. Kathy Woodlock for her help in preparing this manuscript. These studies were supported in part by Grants no. AM-15398 and AM-19155 from the National Institute of Arthritis, Metabolism and Digestive Diseases, Department of Health, Education and Welfare; by a grant from the Juvenile Diabetes Foundation; and under United States Energy Research and Development Administration Contract EY-76-S-02-3017.000 with the New England Deaconess Hospital.

1. Lindall, A., Steffes, M. & Sorenson, R. (1969) "Immunoassayable insulin content of subcellular fractions of rat islets," *Endocrinology* 85, 218-223.
2. Sharp, D. W., Kemp, C. B., Knight, M. J., Ballinger, W. F. & Lacy, P. E. (1973) "The use of Ficoll in the preparation of viable islets of Langerhans from the rat pancreas," *Transplantation* 16, 686-689.
3. Grillo, T. A. I., Whitty, A. J., Kirkman, H., Foa, P. P. & Kobernick, S. D. (1967) "Biological properties of a transplantable islet-cell tumor of the golden hamster. I. Histology and histochemistry," *Diabetes* 16, 409-414.
4. Sodoyez, J. C., Luyckx, A. S. & Lefebvre, P. J. (1969) "Biological

- properties of a transplantable islet-cell tumor of the golden hamster. II. Insulin content of the tumor and some metabolic characteristics of the tumor-bearing animals," *Diabetes* 16, 415-417.
5. Chick, W. L., Warren, S., Chute, R. N. & Lauris, V. (1976) "A transplantable rat insulinoma," *Diabetes* 25, Suppl. 1, 344.
 6. Chan, S. J., Labrecque, A. D., Hofmann, C., Diakoumis, K., Lauris, V., Chick, W. L. & Steiner, D. F. (1976) "Studies of insulin biosynthesis in streptozotocin- and radiation-induced β -cell tumors from rat pancreas," *Diabetes* 25, Suppl. 1, 343.
 7. Duguid, J. R., Steiner, D. F. & Chick, W. L. (1976) "Partial purification and characterization of the mRNA for rat preproinsulin," *Proc. Natl. Acad. Sci. USA* 73, 3539-3543.
 8. Chick, W. L., King, D. L. & Lauris, V. "Tissue culture of pancreatic beta cells," in *Diabetes Research in the Future, Meeting of the Minkowsky Prize Winners, Symposia Medica Hoechst*, Capri, April 14-16, 1976, (F. K. Schattauer Verlag, Stuttgart), in press.
 9. Chick, W. L., King, D. L. & Lauris, V. "Techniques for the preparation and maintenance of pancreatic beta cell monolayer cultures," in *Pancreatic Beta Cell Culture, Fifth Workshop Conference Hoechst*, Kitzbühel, Austria, October 5-9, 1976, eds. Chick, W. L. & Wasielewski, E. v. (Excerpta Medica, Amsterdam), in press.
 10. Warren, S., Carlstein, R. G., Steinke, J. & Chute, R. N. (1964) "Island-cell tumors in irradiated rats in parabiosis," *Proc. Soc. Exp. Biol. Med.* 115, 910-912.
 11. Boschetti, A. E. & Moloney, W. C. (1966) "Observations on pancreatic islet cell and other radiation-induced tumors in the rat," *Lab. Invest.* 15, 565-575.
 12. Rosen, V. J., Castenera, T. J., Kimeldorf, D. J. & Jones, D. C. (1962) "Pancreatic islet cell tumors and renal tumors in the male rat following neutron exposure," *Lab. Invest.* 11, 204-210.
 13. Warren, S., LeCompte, P. & Legg, M. (1966) "Gomori's aldehyde fuchsin," in *The Pathology of Diabetes Mellitus*, (Lea & Febiger, Philadelphia, Pa.), pp. 504-505.
 14. Like, A. A. & Orci, L. (1972) "Embryogenesis of the human pancreatic islets. A light and electron microscopic study," *Diabetes* 21, Suppl. 2, 511-534.
 15. Soeldner, J. S. & Slone, D. (1965) "Critical variables in the radioimmunoassay of serum insulin using the double antibody technic," *Diabetes* 14, 771-779.
 16. Chick, W. L., Lauris, V., Flewelling, J. H., Andrews, K. A. & Woodruff, J. M. (1973) "Effects of glucose on beta cells in pancreatic monolayer cultures," *Endocrinology* 92, 212-218.
 17. Grunt, J. A., Pallotta, J. A. & Soeldner, J. S. (1970) "Blood sugar, serum insulin and free fatty acid interrelationships during intravenous tolbutamide testing in normal young adults and in patients with insulinoma," *Diabetes* 19, 122-126.
 18. Turner, R. C., Oakley, N. W. & Nabarro, J. D. N. (1971) "Control of basal insulin secretion, with special reference to the diagnosis of insulinoma," *Br. Med. J.* 2, 132-135.
 19. Melani, F., Ryan, W. G., Rubenstein, A. H. & Steiner, D. F. (1970) "Proinsulin secretion by a pancreatic beta-cell adenoma," *N. Engl. J. Med.* 283, 713-719.
 20. Weir, G. C., Goltsov, P. C., Steinberg, E. P. & Patel, Y. C. (1976) "High concentration of somatostatin immunoreactivity in chicken pancreas," *Diabetologia* 12, 129-132.
 21. Latta, J. S. & Harvey, H. T. (1942) "Changes in the islets of Langerhans of the albino rat induced by insulin administration," *Anat. Rec.* 82, 281-295.
 22. Logothetopoulos, J., Kaneko, M., Wrenshall, G. A. & Best, C. H. (1964) "Zinc, granulation and extractable insulin of islet cells following hyperglycemia or prolonged treatment with insulin," in *The Structure and Metabolism of the Pancreatic Islets*, eds. Brodin, S. E., Hellman, B. & Knutson, H. (Pergamon Press, Oxford), pp. 333-347.
 23. Turner, R. C. & Johnson, P. C. (1973) "Suppression of insulin release by fish insulin induced hypoglycemia," *Lancet* i, 1483-1485.
 24. Horowitz, D. C., Rubenstein, A. H., Reynolds, C., Molnar, G. D. & Yanaihara, N. (1975) "Prolonged suppression of insulin release by insulin-induced hypoglycemia: Demonstration by C-peptide assay," *Horm. Metab. Res.* 7, 449-452.
 25. Alberti, K. G. M. M., Christensen, S. E., Iversen, J., Seyer-Hansen, K., Christensen, N. J., Hansen, A. P., Lundbaek, K. & Orskov, H. (1973) "Inhibition of insulin secretion by somatostatin," *Lancet* ii, 1299-1301.
 26. Sato, G. & Buonassisi, V. (1964) "Hormone secreting cultures of endocrine tumour origin," *Natl. Cancer Inst. Monogr.* 13, 81-90.
 27. Sato, G. & Yasumura, Y. (1966) "Retention of differentiated function in dispersed cell culture," *Trans. N.Y. Acad. Sci.* 28, 1063-1079.
 28. Rakieten, N., Gordon, B. S., Beaty, A., Cooney, D. A., Davis, R. D. & Schein, P. S. (1971) "Pancreatic islet cell tumors produced by the combined action of streptozotocin and nicotinamide," *Proc. Soc. Exp. Biol. Med.* 137, 280-283.
 29. Volk, B. W., Wellmann, K. F. & Brancato, P. (1973) "Fine structure of rat islet cell tumors induced by streptozotocin and nicotinamide," *Diabetologia* 10, 37-44.
 30. Dixit, P. K. & Bauer, G. E. (1976) "Studies on rats with islet beta cell tumors induced by nicotinamide and streptozotocin," *Proc. Soc. Exp. Biol. Med.* 152, 232-236.